

Herpes Simplex Esophagitis: A rare case of primary HSV-1 and HSV-2 co-infection in an immunocompetent host

Samier J. Deen, D.O.¹, Noor F. Basharat, B.S.², Gavin Levinthal, M.D.¹, Kara Asbury, M.D.¹, Dana Sall, M.D.¹

¹[HonorHealth/Thompson Peak medical Center, 7400 E. Thompson Peak Pkwy, Scottsdale, AZ, 85255]
²[University of Arizona College of Medicine - Phoenix, 475 N 5th St, Phoenix, AZ 85004]

INTRODUCTION

- Herpes simplex esophagitis (HSE) is commonly recognized as an opportunistic infection in the immunocompromised, although it is seldom reported in those with immunocompetence.¹
- Often attributed to viral reactivation of herpes simplex virus type 1 (HSV-1) and rarely type 2 (HSV-2) in immunocompromised individuals, HSE is curiously more often associated with primary infection in immunocompetent hosts.¹⁻²

CASE DESCRIPTION

History

This is an 18-year-old male with a PMHx significant for attention-deficit hyperactivity disorder who presents with a one-week history of fevers, sore throat, intractable nausea/vomiting, and epigastric abdominal pain.

The patient reports unintentional weight loss of 22 lb. since onset of symptoms. Patient admitted to smoking marijuana, vaping and drinking 1-2 beers weekly. He was sexually active with one female partner, reporting inconsistent condom use and uncertainty about partner's STI history. No NSAID or aspirin use. No FMHx of IBD or colon cancer. No prior EGD or colonoscopy. No other symptom complaints.

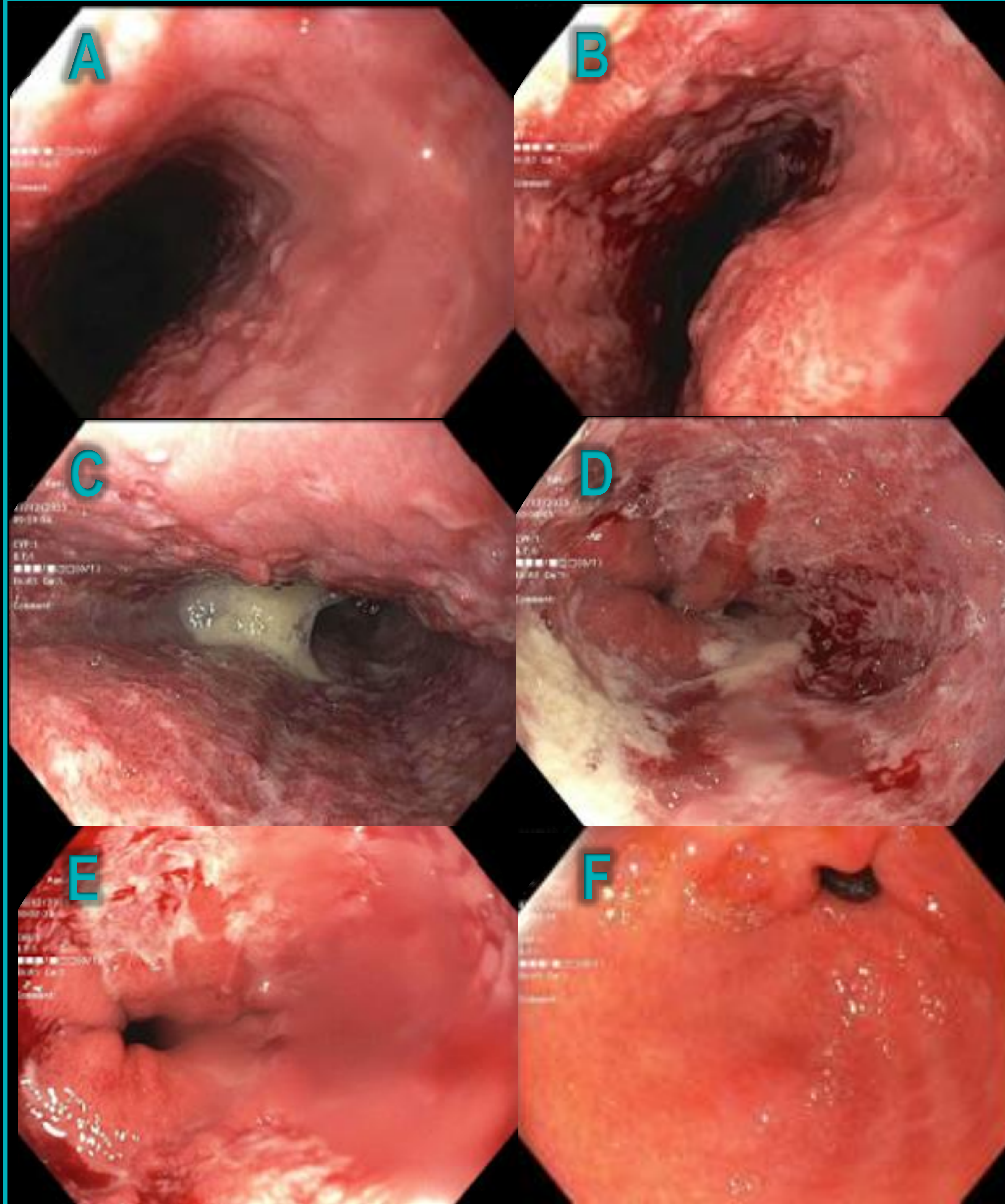
Physical Exam

- Vital signs: T 97.7 °F, HR 81, BP 140/87, RR 16, SpO2 98% RA, BMI 34.2
- General: Uncomfortable-appearing
- Abdominal exam: Epigastric tenderness to palpation

Hospital Course

- CBC/CMP within normal limits.
- CT abdomen pelvis with IV contrast demonstrated thickening of the ascending colon consistent with colitis. US gallbladder with no acute findings.
- The patient was admitted to the inpatient service for colitis and was initiated on piperacillin-tazobactam.
- Stool studies were obtained including fecal calprotectin, lactoferrin, rotavirus antigen, Yersinia culture, and stool culture with Shiga toxin. All stool studies were negative with the exception of fecal calprotectin which was elevated at 175.0 mcg/g (<=49.0 mcg/g)
- During his hospitalization, the patient began to endorse a sore throat, odynophagia, and retrosternal pain in the setting of recurrent emesis.
- Gastroenterology evaluated the patient. Antibiotics were discontinued and the patient was initiated on IV proton pump inhibitor (PPI) treatment. He underwent esophagogastroduodenoscopy (EGD) with findings of erythematous mucosa in the gastric body and antrum as well as severe ulcerative esophagitis (Figure 1A-E).
- Biopsies were obtained from the gastric and esophageal regions, and pathology demonstrated herpetic esophagitis with ulceration and qualitative immunostains incorporating both HSV-1 (Figure 2A) and focal HSV-2 (Figure 2B).
- Infectious disease evaluated the patient. Fourth-generation HIV antigen/antibody screen and HSV IgG serology testing were negative. The patient was initiated on IV acyclovir and transitioned to oral acyclovir to complete a 10-day course. The patient was discharged home with oral acyclovir three times daily and oral PPI twice daily.
- He was advised to follow up closely with gastroenterology for colonoscopy and repeat EGD in three months.

ESOPHAGOGASTRODUODENOSCOPY (Figure 1)



HISTOPATHOLOGY (Figure 2)

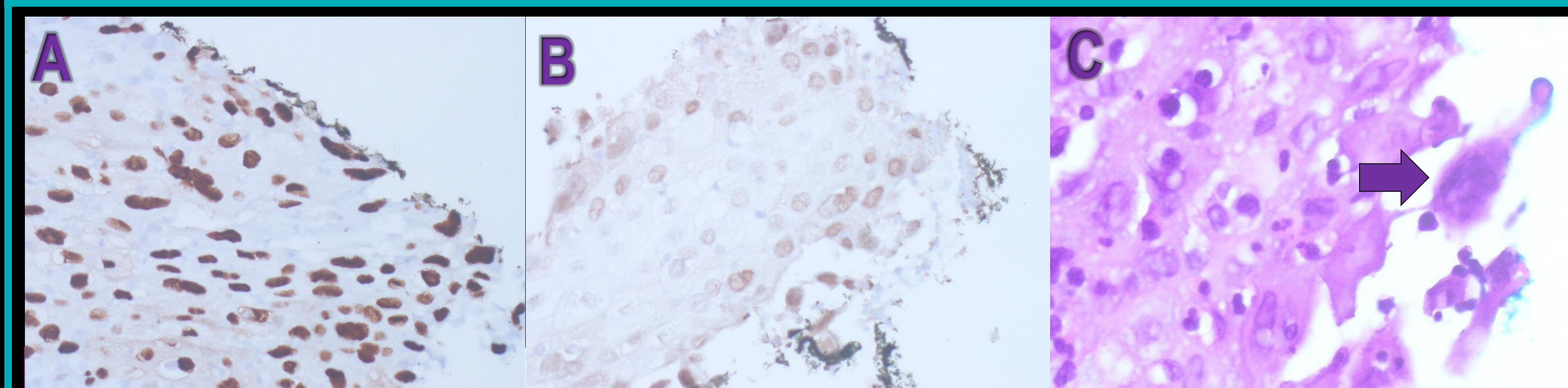


Fig. 1: (A, B, C, D) Markedly inflamed esophagus (lower third) compatible with severe ulcerative esophagitis. Similar ulcerations preceding GE junction (E). Diffuse moderately erythematous mucosa was found in the gastric antrum (F).
Fig. 2: HSV-1 positive stain brown nuclei (A). HSV-2 positive stain brown nuclei (B). HSV-infected multinucleated giant cell (C).

DISCUSSION

- Although esophagitis due to HSV-1 is uncommon in immunocompetent hosts, cases associated with coinfection of both HSV-1 and HSV-2 are exceedingly rare.
- The classic triad of HSE consists of fever, odynophagia, and retrosternal pain.¹
- Diagnostic modalities include HSV serology, HSV polymerase chain reaction (PCR) testing, endoscopy, and histopathology.
- Endoscopic findings typically consist of erosions and ulcers.^{2,4}
 - In the earlier phase of infection, vesicle formation is said to occur with evolution to small punched-out lesions on endoscopy.^{2,4}
 - In the later stages, multiple ulcers coalesce and form a map-like appearance as appreciated in Figure 1D.^{2,4}
 - The location of ulcerations classically involves the middle to distal (lower third) esophagus.^{2,4}
- Upon review of available literature, there is a paucity of other reports documenting biopsy-confirmed coinfection with HSV-1 and HSV-2.³
 - This may be the result of true low incidence of co-infection or unreliable sampling.
 - According to available literature, the HSV-2 component on immunostaining often may not reflect true co-infection but perhaps cross-reactivity of HSV-1.⁵
 - In-situ hybridization can exclude the possibility of cross-reactivity but is not routinely performed as it is labor-intensive.⁵
- Potential therapeutic interventions should consider the immune status of the patient, reserving antiviral therapy for immunocompromised hosts given the unknown benefit in immunocompetent individuals.¹

CONCLUSION

- HSE remains rarely reported in immunocompetent individuals; however, the limited reports of HSE in immunocompetent individuals may be the result of underdiagnosis.¹
- Therefore, HSE should be included as part of the differential for young patients regardless of immune status to prompt early endoscopy and histopathological testing, especially those presenting with the classic triad of fever, odynophagia, and retrosternal pain.¹

REFERENCES

- Canalejo, Eduardo, Garcia Duran, Fernando, Cabello, Noemi, Garcia Martinez, Jesus. Herpes Esophagitis in Healthy Adults and Adolescents: Report of 3 Cases and Review of the Literature. *Medicine (Baltimore)*. 2010;89(4):204-210. doi:10.1097/MD.0b013e3181e949ed
- Naqvi HA, Bandaru S, Janvier AL, Yousaf MN. Herpes simplex virus-2-associated esophagitis in immunocompetent host. *Prz Gastroenterol*. 2021;16(3):248-251. doi:10.5114/pg.2020.100757
- Hopkins C, Bansari A, Ladna M, Dideban B. Prolonged Intractable Hiccups Associated with HSV (I&II) Esophagitis and H. pylori Gastritis. *Case Rep Infect Dis*. 2023;2023:3561895. doi:10.1155/2023/3561895
- Wang HW, Kuo CJ, Lin WR, et al. Clinical Characteristics and Manifestation of Herpes Esophagitis: One Single-center Experience in Taiwan. *Medicine (Baltimore)*. 2016;95(14):e3187. doi:10.1097/MD.0000000000003187
- Lefkowitz, J. H. (2015). *Anatomic pathology: Board review (2nd ed.)*. Elsevier/Saunders.